

ONLY WITH

VIMAGO

SMALL ANIMAL CASE STUDY REVIEW

By Dr. Robert O'Brien, DVM, DACVR

Left-sided bacterial otitis media and externa with presumed encephalitis and meningitis

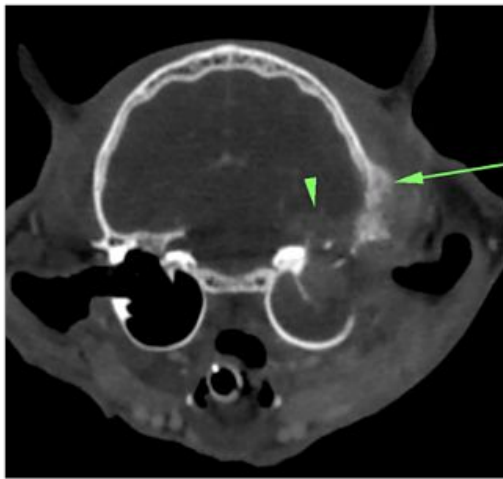


Figure 1

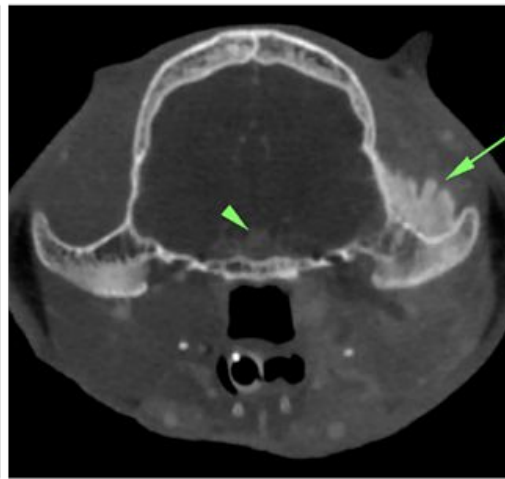


Figure 2

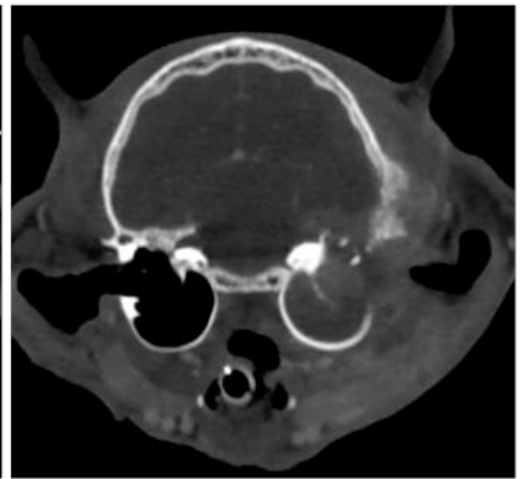


Figure 3

PATIENT

4-year-old male neutered domestic short haired cat that presented with a history of chronic ear scratching. Recently the patient developed a head tilt. On physical examination the patient had soft tissue swelling to the left base of the skull, head tilt, and nystagmus. The left ear canal was occluded at the junction of the horizontal and vertical ear canal regions.

IMAGE PROTOCOL

A survey and post-i.v. contrast CT was performed of the head. The contrast dose was 2ml ml/lb BW of Iohexol (300mg/ml iodine) contrast media; given as a bolus prior to image initiation.

FINDINGS

The right ear canal and tympanic bulla was normal (FIG1). Left-sided soft tissue swelling was seen in the subcutaneous and deeper fascial layers of the head surrounding the left ear base. This region had mild contrast enhancement. The majority of the left horizontal ear canal and tympanic bulla were filled with mild to moderately enhancing soft tissue attenuating material. There was lysis of the lateral dorsal wall and thickening of the ventral wall the left tympanic bulla. There was lysis of the skull base contiguous with the left tympanic bulla and in this region was a irregular shaped and moderately contrast enhancing mass lesion. Irregular active-appearing, speculated to palisading periosteal new bone formation was seen on the adjacent occipital and zygomatic bones of the left skull base. No enlarged lymph nodes or pulmonary lesions were identified. The pituitary gland was of normal size (FIG 2).

Left-sided bacterial otitis media and externa with presumed encephalitis and meningitis

IMAGING DIAGNOSIS

Left-sided aggressive tympanic bulla disease with brain involvement: a. Otitis media (or neoplastic infiltration: carcinoma, soft tissue sarcoma) b. Reactive skull periosteal proliferation c. Soft tissue edema (or hemorrhage) Normal right tympanic bullae and ear canal.

FINAL DIAGNOSIS

Left-sided bacterial otitis media and externa with presumed encephalitis and meningitis.

DISCUSSION POINT

Imaging of the middle ear can be very challenging with conventional radiographs. Superimposition of contralateral structures often precludes complete or accurate characterization of lesions of the tympanic bulla and adjacent structures. ***The Vimago™ HD CT Scanner provides excellent spatial resolution of the bone and soft tissue structures of the ear base.*** Contrast enhancement is excellent with injected contrast media. As noted in this case, the enhancement in the brain was vital for staging this disease, although not exclusive for the differentiation between benign and malignant differentials. Evaluation of the contralateral bulla, assessment of adenopathy and ability to detect concurrent nasal and pulmonary lesions is vital for the complete workup of middle ear disease in cats and dogs. This can all be accomplished within a few minutes of imaging with the Vimago™ veterinary CT scanner, providing detailed high-resolution image sets.



LEARN MORE:

SALES@EPICAMED.COM | EPICAMED.COM/PRODUCTS/VIMAGO | PHONE: 855.993.7422